

# Complete Lung Atelectasis following Caesarean Section in a Case of Imminent Eclampsia: A Case Report

RAJASRI YALIWAL<sup>1</sup>, LAXMI SANGOLLI<sup>2</sup>, ARUNA BIRADAR<sup>3</sup>, SONA TEJASWI<sup>4</sup>, NAMITA GUPTA<sup>5</sup>

(CC) BY-NC-ND

## ABSTRACT

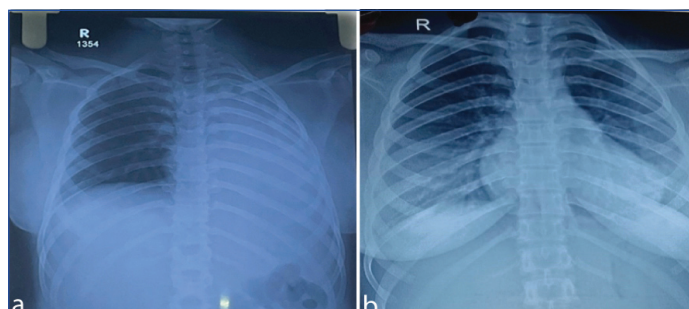
In the early postpartum period, acute life-threatening problems can occur and cause maternal morbidity and mortality. In the present case report, a 19-year-old primipara had undergone caesarean delivery following which she developed breathlessness, tachycardia and fall in oxygen saturation after 14 hours of surgery. Her Chest X-Ray (CXR) report confirmed a complete collapse of the left lung. Contrast-enhanced Computed Tomography (CECT) of the thorax showed a complete collapse of the left lung due to obstruction at the level of the proximal main stem bronchus. Medical management with mucolytics was administered. The patient showed improvement clinically and a repeat CXR after 24 hours showed normal lung findings with complete resolution of collapse and medical management was continued. The patient recovered progressively and follow-up of the patient was uneventful. This is a rare case of development of respiratory distress and atelectasis, hence proper diagnosis is essential.

**Keywords:** Breathlessness, Mucolytics, Spinal anaesthesia, Tachycardia

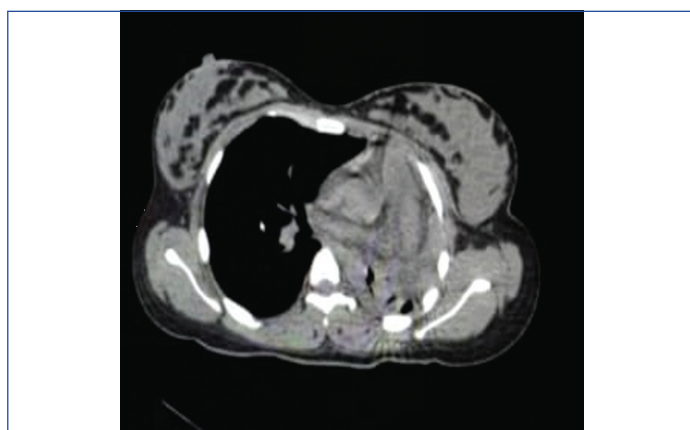
## CASE REPORT

A 19-year-old married woman, primigravida, belonging to lower socio-economic status according to Modified Kuppuswamy classification presented on immediate postoperative day following emergency caesarean delivery under spinal anaesthesia in view of foetal distress, suddenly developed breathlessness and fall in oxygen saturation level. The patient had a history of Upper Respiratory Tract Infection (URTI) five days prior to admission and was on treatment. The patient was diagnosed with preeclampsia one week before admission for which she didn't take the treatment. She presented with imminent signs like headache one day prior to admission with blurring of vision which was sudden in onset. On examination, she had a pulse rate of 120 bpm, blood pressure of 120/90 mmHg, respiratory rate of 22 cycles per minute, and oxygen saturation was 82%. The uterus was well contracted and minimal per-vaginal bleeding was noted. On auscultation of the chest, right-side air entry was normal, and complete absence of breath sounds was noted on the left-side. A cardiac examination revealed no signs of hypoperfusion and no murmurs or gallop. She was shifted to the Obstetric Intensive Care Unit (OICU) immediately and oxygen support was given at a rate of 8 L/min via oxygen mask. Blood investigations showed haemoglobin of 10 g/dL, total leucocyte count of 14.92 103/uL, platelet count of 2.42 lacs, and D-dimer of 5998 ng/mL. Arterial blood gas analysis was normal and the electrocardiogram revealed diffuse flattened T waves and sinus tachycardia. Moderate tricuspid regurgitation was seen on transthoracic echocardiography, but there was no right chamber dilation or paradoxical interventricular septal movement. With preserved left ventricular systolic and diastolic functioning and no evidence of an elevated left ventricular filling pressure, a left heart evaluation indicated no structural abnormalities. Complete atelectasis of the left lung was confirmed by CXR, and there were no discernible alterations in the right lung [Table/Fig-1 a,b]. CECT scan revealed that the left lung had completely collapsed because of obstruction at the level of the left main stem bronchus [Table/Fig-2].

The patient was given oxygen support via an oxygen hood, and continuous monitoring of oxygen saturation levels and vitals was done. Medical management was given with intravenous piperacillin and tazobactam 4.5 g intravenously, twice daily for one week along



**[Table/Fig-1]:** a) Chest X-Ray (CXR) (left panel) shows opacification of the entire left hemithorax and elevation of the left diaphragm; b) After 24 hours from mucolysis, regression of this opacification was observed.



**[Table/Fig-2]:** CECT showing complete collapse of the left lung with obstruction at the proximal left main stem bronchus.

with proton pump inhibitors. Nebulisation with acetylcysteine was continued for one week every sixth hourly. After receiving medical care, the patient remained asymptomatic, had no dyspnoea, and had a normal oxygen saturation level. Blood pressure and heart rate were restored to their normal levels. Following 24 hours, the CXR revealed no abnormalities [Table/Fig-1b]. The patient was discharged uneventfully after seven days. A seven-day broad-spectrum oral antibiotic therapy with amoxicillin and clavulanate was administered and the patient was followed-up after five days

with improvement in the clinical condition and was also weaned off from antibiotic therapy and antihypertensive drugs.

DISCUSSION

The present case was of a 19-year-old married woman, primigravida who presented with sudden acute hypoxic respiratory depression, the suspected diagnosis being pulmonary embolism. Complete left lung atelectasis was seen on a CXR, hence, it was necessary to perform a thoracic CECT scan to rule out pulmonary embolism, as a study conducted by Meira MN et al., also suggested that chances of lung atelectasis are more following caesarean delivery [1]. Also, this case showed severe atelectasis of the left lung, caused by an obstruction in the proximal left main stem bronchus on CT scan. As there were no other predisposing factors in this case, we believe that the cause might be the accumulation of post-nasal secretion leading to the formation of mucous plug secondary to URTI. Since the patient was taken for caesarean section under spinal anaesthesia, the probability of blood clot obstruction was ruled out and her nil per oral status was six hours prior to surgery and probable obstruction due to aspiration of food particles was ruled out. After 14 hours, symptoms appeared, most likely as a result of the mucous plug extending into the proximal main stem bronchus. The ideal course of treatment for a patient who is haemodynamically stable and who has a normal gas exchange is meticulous follow-up. Repeated episodes of dyspnoea and arterial desaturation, in this case, showed that the mucus plug needed to be removed. The initial treatment guidelines according to Helen MH et al., indicate pre-oxygenation and airway maintenance [2]. Masukume G et al., also medically managed their case of lung obstruction by giving higher antibiotics, hydrocortisone injection, and analgesic support, where radiologists suspected the cause to be tuberculosis but despite that, the patient was managed by the above treatment. If unsuccessful, either an en bloc or piecemeal forceps extraction or clot dislodging using a Fogarty catheter is the next step [3,4]. The present case was successfully managed with medication itself with the help of nebulisation with mucolytics, without recurrence of

symptoms. Broad-spectrum antibiotics were recommended since secondary atelectasis frequently becomes infected, irrespective of the source of obstruction. Whereas, Vajo Z and Parish JM in their study went for endobronchial thrombolysis with streptokinase for airway obstruction as they found blood clot being the reason for obstruction [5]. Chawla L et al., had a case where a mucus plug was causing obstruction; they proceeded with plug removal leading to immediate improvement in the clinical condition of the patient [6]. The index case carries valuable importance as under spinal anaesthesia, development of respiratory distress and atelectasis are rare. So, the present case signifies consideration for further studies and evaluation.

CONCLUSION(S)

Pregnant women's postoperative complications should be carefully assessed. In the postpartum period, prompt diagnosis and management will reduce morbidity and mortality. Acute onset respiratory depression should be diagnosed and the cause should be ruled out rapidly to prevent maternal mortality.

REFERENCES

[1] Meira MNC, Carvalho CRR, Galizia MS, Borges JB, Kondo MM, Zugaib M, et al. Atelectasis observed by computerized tomography after Caesarean section. Br J Anaesth. 2010;104(6):746-50.

[2] Helen MH, Melvin RP, Richard SI. Acute respiratory failure in pregnancy. J Intensive Care Med. 1989;4:01-34.

[3] Masukume G, Sengurayi E, Moyo P, Feliu J, Gandanhamo D, Ndebele W, et al. Massive hemoptysis and complete unilateral lung collapse in pregnancy due to pulmonary tuberculosis with good maternal and fetal outcome: A case report. BMC Res Notes. 2013;6:335. Doi: 10.1186/1756-0500-6-335. PMID: 23968230; PMCID: PMC3765411.

[4] Wong AY, Fung LN. Pulmonary atelectasis following spinal anaesthesia for caesarean section. Anaesth Intensive Care. 2006;34(5):687.

[5] Vajo Z, Parish JM. Endobronchial thrombolysis with streptokinase for airway obstruction due to blood clots. Mayo Clin Proc. 1996;71:595-96.

[6] Chawla L, Rajaram S, Maurya P, Saini L, Gupta RK, Singh M. Unusual cause of acute respiratory compromise in a postpartum patient. Eur J Obstet Gynecol Reprod Biol X. 2022;16:100166. Doi: 10.1016/j.eurox.2022.100166. PMID: 36247702; PMCID: PMC9554818.

PARTICULARS OF CONTRIBUTORS:

- 1. Professor, Department of Obstetrics and Gynaecology, Shri B.M. Patil Medical College Hospital and Research Centre, BLDE (DU), Vijayapura, Karnataka, India.
- 2. Associate Professor, Department of Obstetrics and Gynaecology, Shri B.M. Patil Medical College Hospital and Research Centre, BLDE (DU), Vijayapura, Karnataka, India.
- 3. Professor, Department of Obstetrics and Gynaecology, Shri B.M. Patil Medical College Hospital and Research Centre, BLDE (DU), Vijayapura, Karnataka, India.
- 4. Junior Resident, Department of Obstetrics and Gynaecology, Shri B.M. Patil Medical College Hospital and Research Centre, BLDE (DU), Vijayapura, Karnataka, India.
- 5. Junior Resident, Department of Obstetrics and Gynaecology, Shri B.M. Patil Medical College Hospital and Research Centre, BLDE (DU), Vijayapura, Karnataka, India.

NAME, ADDRESS, E-MAIL ID OF THE CORRESPONDING AUTHOR:

Dr. Aruna Biradar,  
Professor, Department of Obstetrics and Gynaecology, Shri B.M. Patil Medical College Hospital and Research Centre, BLDE (DU), Vijayapura-586103, Karnataka, India.  
E-mail: aruna.biradar@bldedu.ac.in

AUTHOR DECLARATION:

- Financial or Other Competing Interests: None
- Was informed consent obtained from the subjects involved in the study? Yes
- For any images presented appropriate consent has been obtained from the subjects. Yes

PLAGIARISM CHECKING METHODS: [Jain H et al.]

- Plagiarism X-checker: Oct 06, 2023
- Manual Googling: Dec 26, 2023
- iThenticate Software: Apr 20, 2024 (1%)

ETYMOLOGY: Author Origin

EMENDATIONS: 9

Date of Submission: Oct 04, 2023  
Date of Peer Review: Dec 11, 2023  
Date of Acceptance: Apr 22, 2024  
Date of Publishing: Jun 01, 2024